60 yr
Male Caucasian

Vent. rate	61	BPM
PR interval	172	ms
QRS duration	84	ms
QT/QTc	408/411	ms
P–R–T axes	62 43	91

#12

60 year old active male with persistent 8/10 chest pain, he runs daily.

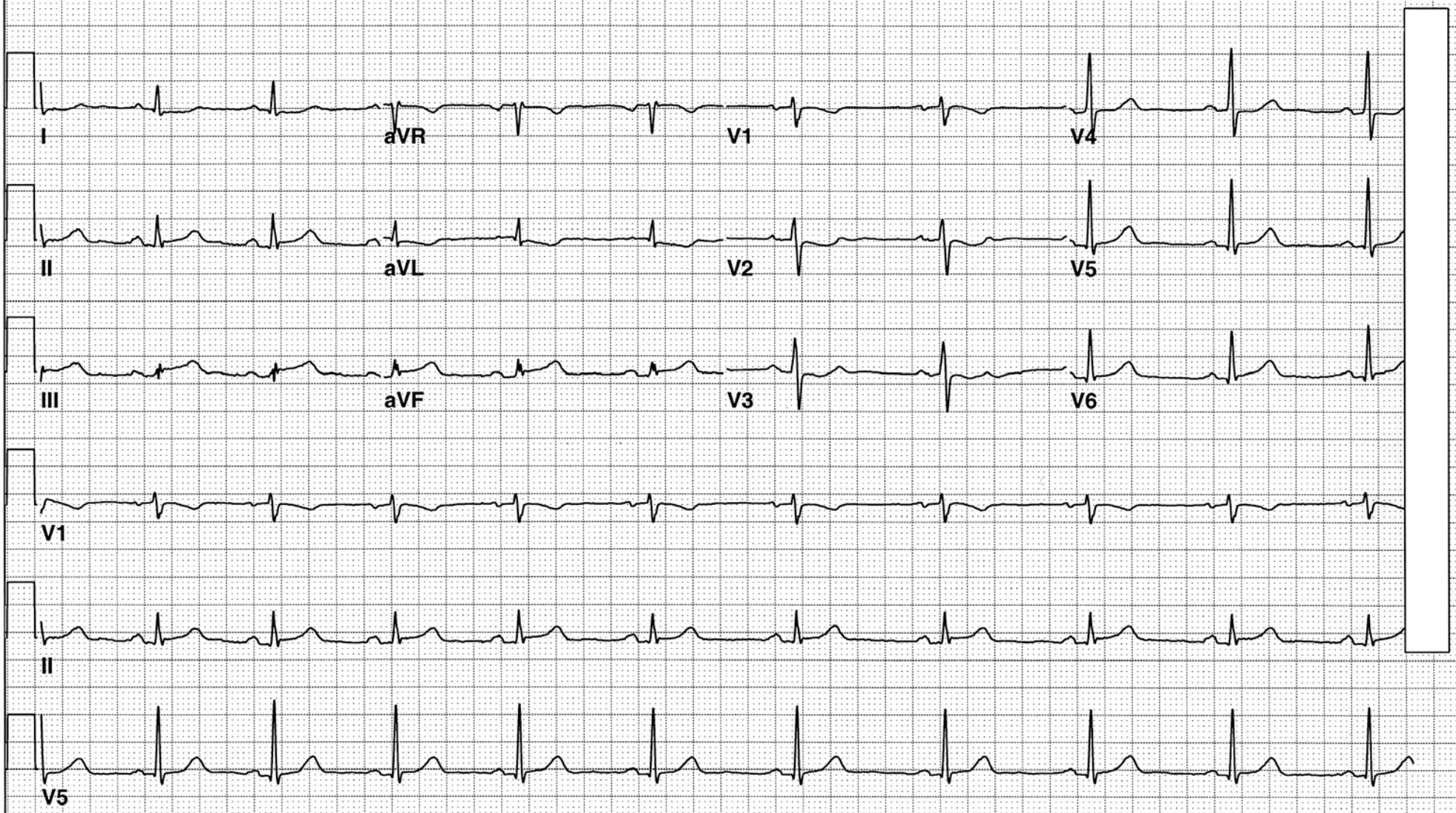

25mm/s 10mm/mV 100Hz 005B 12SL 206

EKG #12

Normal Sinus Rhythm
Inferior Injury/Infarct
Reciprocal ST, T Anterior

Acute MI

Acute Injury Pattern for Lytics

- ST Elevation > 1 mm in two continuous leads
- ST Convex (+/-)
- Chest Pain with New LBBB

- Non Q WavesMI-many non patterns consider GP IIb/IIIa

Anterior ST Changes

1. Anterior Ischemia
2. Anterior Subendocardial Injury
3. Posterior MI
4. Persistent Juvenile Pattern
5. RBBB
6. RVH + Strain
7. Hypokalemia
8. Reciprocal Changes from MI

RV Infactions

- 1 mm ST Elevation in $V3^R$, $V4^R$
- Associated with inferior MI's

- Right-Sided Precordial Tracings on all acute inferior MI's