## TESTS FOR JOINT STABILITY

The knee joint owes its stability to a strong and extensive joint capsule, collateral ligaments, cruciate ligaments, and surrounding muscles and tendons. The following tests evaluate the strength and integrity of those structures.

### *Collateral Ligaments*

Ask the patient to lie supine on the table with one knee flexed just enough so that it unlocks from full extension. To test the medial collateral ligament, secure his ankle with one hand and place the other hand around the knee so that your thenar eminence is against the fibular head. Then, push medially against the knee and laterally against the ankle in an attempt to open the knee joint on the inside (valgus stress) (Fig. 44). Palpate the medial joint line for gapping, which may even be visible. If there is a gap, the medial collateral ligament is not supporting the knee properly. When stress on the injured joint is relieved, you can feel the tibia and femur "clunk" together as they close.

To test the lateral aspect of the knee for stability, reverse the position of your hands, and push laterally against the knee and medially against the ankle to open the knee joint on the lateral side (varus stress). Again, palpate the lateral joint line for any gapping (Fig. 45). As on the medial side, such a gap may be both palpable and visible. Upon the release of varus stress, the tibia and femur may clunk into position as they close.

If your fingers are too short to reach around the knee to palpate the joint lines, secure the patient's foot between your arm and body (in the axilla) so that your hands are free to palpate the joint line. In this way, your body acts as a lever on the foot and applies varus and valgus stress to the knee joint (Figs. 44, 45).

Since the medial collateral ligament is critical to stability, an isolated tear of this ligament leads to joint instability, whereas a similar defect in the lateral collateral ligament may have little effect either way. Most ligamentous injuries around the knee occur on the medial side.

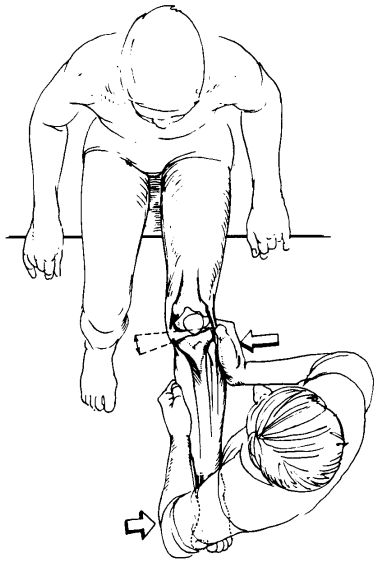

**Fig. 44.** To test the medial collateral ligament, apply valgus stress to open the knee joint on the medial side.

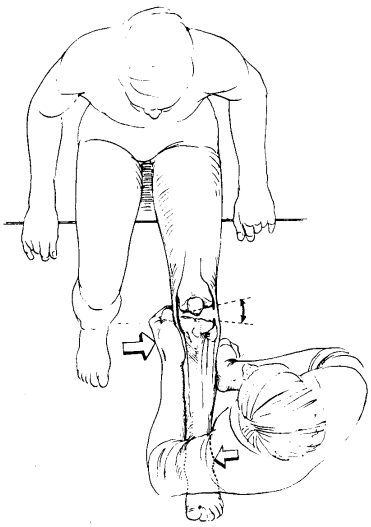

**Fig. 45.** To test the lateral knee for stability, apply varus stress to open the knee joint on the lateral side.

### *Cruciate Ligaments*

The anterior and posterior cruciate ligaments are instrumental in preventing anterior and posterior dislocation of the tibia on the femur. These ligaments are intracapsular, originating on the tibia and inserting into the inner sides of the femoral condyles.

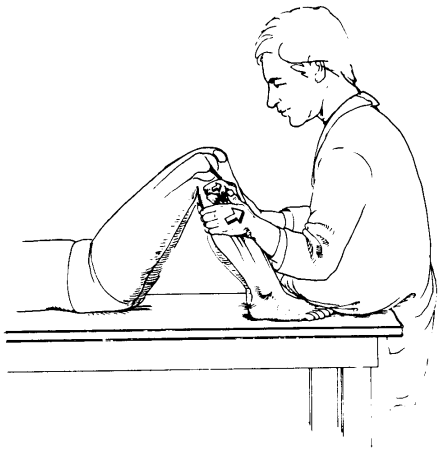

**Fig. 46.** Position for eliciting the anterior draw sign.

To test the integrity of the anterior cruciate ligament, have the patient lie supine on the examination table with his knees flexed to 90° and his feet flat on the table. Position yourself on the edge of the table so that you can stabilize his foot by sitting on it. Then cup your hands around his knee, with your fingers on the area of insertion of the medial and lateral hamstrings and your thumbs on the medial and lateral joint lines. Now, draw the tibia toward you (Fig. 46); if it slides forward from under the femur (positive anterior draw sign), the anterior cruciate ligament may be torn (Fig. 47). A few degrees of anterior draw are normal if an equal amount is present on the opposite side.

When you do find a positive anterior draw sign, it is important to repeat the maneuver with the patient's leg in internal and external rotation. External rotation of the leg tightens the posteromedial portion of the joint capsule; normally, there should then be reduced forward movement of the tibia on the femur, even if the anterior cruciate ligament is torn. Thus, if forward movement with the leg externally rotated is equal to forward movement with the leg in the neutral position, both the anterior cruciate ligament and the posteromedial portion of the joint capsule (and possibly the medial collateral ligament) may be damaged. Internal rotation tightens the structures on the posterolateral side of the knee. Normally, there should be reduced movement when the leg is pulled forward, even if the anterior cruciate ligament is torn. If the amount of forward movement

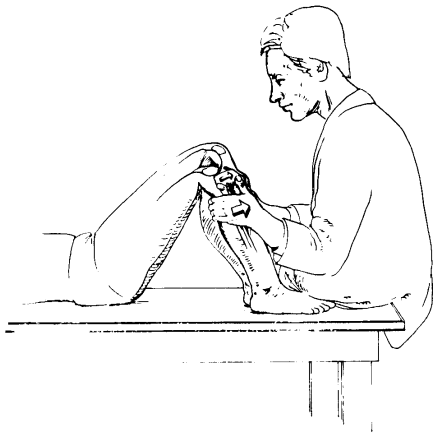

**Fig. 47.** A positive anterior draw sign: Torn anterior cruciate ligament.

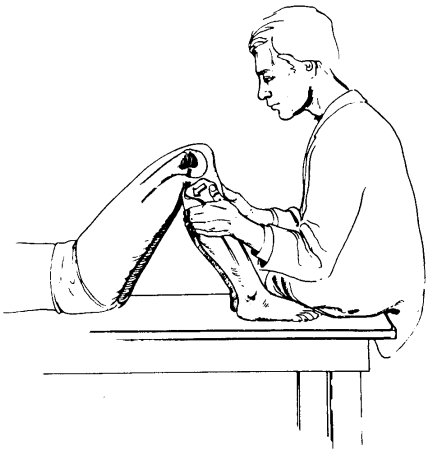

**Fig. 48.** A positive posterior draw sign: Torn posterior cruciate ligament.

of the tibia on the femur in internal rotation is equal to that in the neutral position, both the anterior cruciate ligament and the posterolateral portion of the joint capsule may be torn. The anterior cruciate ligament may be torn in association with tears of the medial collateral ligament.

Test the posterior cruciate ligament in a similar manner. Stay in the same position and push the tibia posteriorly (Fig. 48). If it moves backward on the femur, the posterior cruciate ligament is probably damaged (positive posterior draw sign). The anterior draw sign is more common than the posterior sign, since the incidence of damage to the anterior cruciate is much higher than to the posterior cruciate. In fact, an isolated tear of the posterior cruciate ligament is rare.

These tests for stability of the anterior and posterior cruciate ligaments are usually performed in one continuous motion and have been separated here mainly for the purpose of instruction. All procedures should be performed bilaterally, and all findings compared.

## RANGE OF MOTION

There are three basic movements in the knee joint: (1) flexion (associated with glide), (2) extension (associated with glide), and (3) internal and external rotation.

Flexion and extension are primarily the result of movement between the femur and the tibia. Internal and external rotation involve displacement of the menisci on the tibia, as well as movement between the tibia and the femur. Extension is performed by the quadriceps, while flexion is performed by the hamstrings and gravity. Internal and external rotation (which take place when the knee is slightly flexed) are performed by the reciprocal action of the semimembranosus, semitendinosus, gracilis, and sartorius on the medial side, and the biceps on the lateral side.

### *Active Range of Motion*

The following quick tests determine whether or not there is any gross restriction in a patient's range of knee motion.

**FLEXION.** Ask the patient to squat in a deep knee bend. He should be able to flex both knees symmetrically.

**EXTENSION.** Instruct the patient to stand up from the squatting position, and take careful notice of whether he is able to stand straight, with knees in full extension, or whether one leg is relied upon more than the other during the procedure. You may also instruct him to sit on the edge of the examination table and to extend his knee fully (Fig. 49). The arc of motion from flexion to extension should be smooth. On occasion, a patient may be unable to extend the knee through the last 10° of motion and may be able to finish extension only haltingly, and with great effort. This is referred to as *extension lag* (Fig. 50). It frequently accompanies quadriceps weakness.

Note that the leg cannot be extended fully without some amount of external tibial rotation on the femur because of the physical configuration of the knee joint and its cruciate ligaments (A. Helfet's Helix). The medial femoral condyle is approximately a half-inch longer than the lateral femoral condyle. Therefore, as the tibia moves on the femoral condyles into full extension, it uses all available articulating surface on the lateral side,

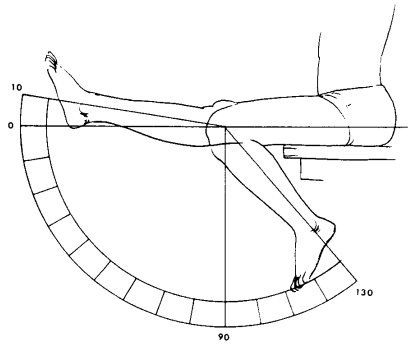


**Fig. 49.** The range of knee motion in flexion and extension.

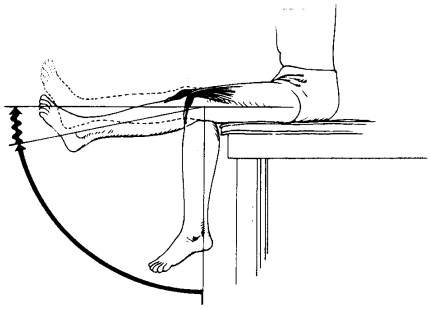

**Fig. 50.** Extension lag, when the last 10° or so of extension are performed haltingly and with difficulty.

## SPECIAL TESTS

McMURRAY TEST. During knee flexion and extension, a torn meniscus may produce a palpable or audible "clicking" in the region of the joint line. Tenderness elicited in palpation of the joint line on either side suggests the possibility of a torn meniscus. Posterior meniscal tears are difficult to identify, and the McMurray test was originally developed to assist in this difficult diagnosis.

Ask the patient to lie supine with his legs flat and in the neutral position. With one hand, take hold of his heel and flex his leg fully (Fig. 58). Then, place your free hand on the knee joint with your fingers touching the medial joint line and your thumb and thenar eminence against the lateral joint line, and rotate the leg internally and externally to loosen the knee joint (Fig. 59). Push on the lateral side to apply valgus stress to the medial side of the joint, while, at the same time, rotating the leg externally (Fig. 60). Maintain the valgus stress and external rotation, and extend the leg slowly as you palpate the medial joint line (Fig. 61). If this maneuver causes a palpable or audible "click" within the joint, there is a probable tear in the medial meniscus, most likely in its posterior half.

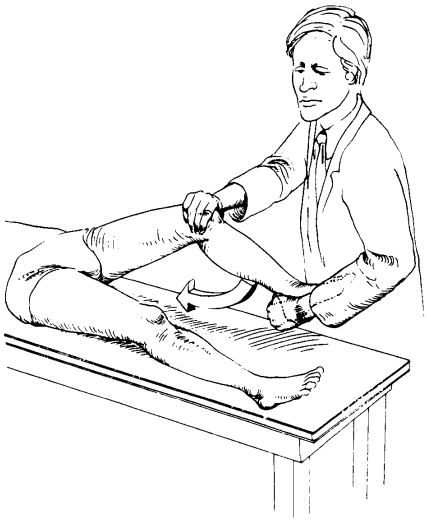

Fig. 58. The McMurray test for meniscal tears. Flex the knee.

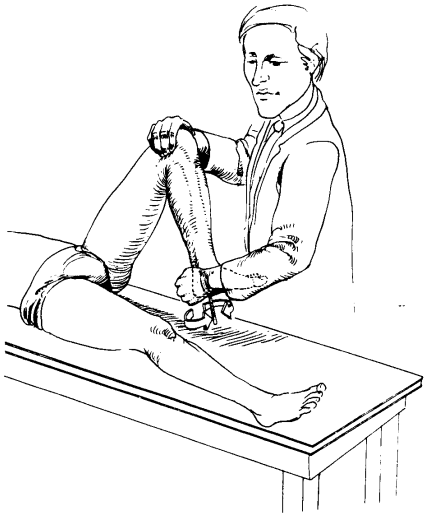

Fig. 59. With the knee flexed, internally and externally rotate the tibia on the femur.

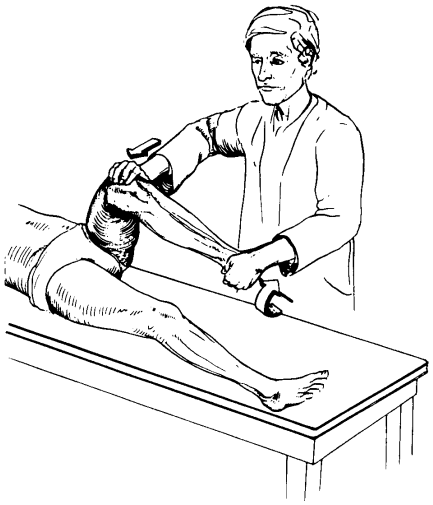

Fig. 60. With the leg externally rotated, place a valgus stress on the knee.

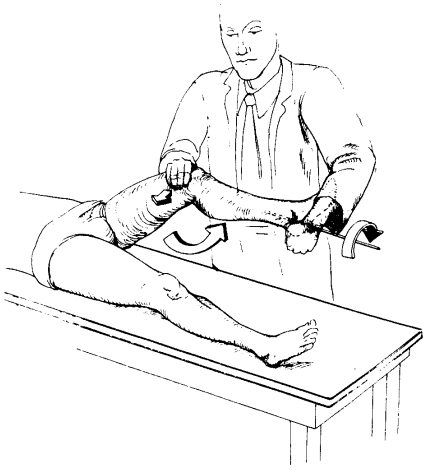

Fig. 61. With the leg externally rotated and in valgus, slowly extend the knee. If click is palpable or audible, the test is considered positive for a torn medial meniscus, usually in the posterior position.